


# Scenario-based Clinical Exam




## Cast Radiograph Evaluation (CRE)/ Case Management Form (CMF)/ Superimposition Preparation Materials & Sample Cases

(Rev. 09.12.2023)

# Disclaimer

- The following sample questions and answers were composed and vetted by a panel of experts in orthodontics and are intended to provide a guide of the types of cases and questions that make up the actual scenario-based clinical examination.
  - After the examination, trained examiners, who are all in-good-standing board certified orthodontists, will score the typed responses using rubrics as guides to their decision making.
  - Rubrics help to create consistency in the decisions the examiners make while grading an examinees typed responses. The rubrics are not absolute, as there may be other acceptable answers that are not listed. However, no credits will be awarded for answers not included in the rubrics.
- 


# Disclaimer Continued

- The ABO has developed multiple versions of the case-based scenario examination to be used during a test administration cycle. Although the set of cases and questions used on the different versions will not all be the same, all versions follow the same content framework as defined by the practice analysis study.
  - Scores will be computed using psychometric equating procedures to ensure that all versions are of the same difficulty level.
  - Review of these sample cases does not guarantee that a candidate will pass the examination.
  - Examinee responses to exam questions will be typed out and should be in numbered list format (i.e., short and concise, no essay responses).
- 



# Cast-Radiograph Evaluation (CRE)

For the Cast-Radiograph Evaluation (CRE), examinees will be shown a series of records which may include: photo montage, images of models, and/or panoramic radiographs (as needed). Examinees will be asked to answer questions based on the information provided.

- Examinees will need to be familiar with grading and critically evaluating models, however, they will NOT be grading models for the Clinical Examination.
  - Examinees will NOT be given the CRE Parameters reference guide during the exam.
  - Examinees need to be prepared to answer some specific critical thinking questions related to the different CRE parameters.
- 

Examinees will need to be familiar with the following CRE parameters as they will NOT be provided during the examination.

Reference - ABO Cast/Radiograph Evaluation	
See <a href="#">Grading System for Casts-Radiographs</a> for entire discussion	
<b>ALIGNMENT/ROTATIONS</b>  0.5 - 1 mm = 1 for each tooth > 1 mm = 2 for each tooth	<b>OCCLUSAL CONTACTS</b>  0 mm = satisfactory ≤ 1 mm = 1 (for each posterior > 1 mm = 2 tooth out of contact)  ** Do <b>not</b> score diminutive distolingual cusps of the maxillary 1 <sup>st</sup> and 2 <sup>nd</sup> molars, nor lingual cusps of the mandibular first premolars. <b>Maximum of 2 points per tooth.</b>
<b>MARGINAL RIDGES</b>  0.5 - 1 mm = 1 (for each interproximal contact > 1 mm = 2 between posterior teeth)  ** Do <b>not</b> include the canine-premolar contact. Do <b>not</b> include the distal of lower 1 <sup>st</sup> premolar.	<b>OCCLUSAL RELATIONSHIP</b>  < 1 mm = satisfactory 1 - 2 mm = 1 (for each maxillary <b>tooth</b> from the > 2 mm = 2 the canines to the 2 <sup>nd</sup> molars)
<b>BUCCOLINGUAL INCLINATION</b>  0 - 1 mm = satisfactory 1.1 - 2 mm = 1 ( for each posterior tooth) > 2 mm = 2  ** Do <b>not</b> score the mandibular 1 <sup>st</sup> premolars nor the distal cusps of the second molars.	<b>INTERPROXIMAL CONTACTS</b>  0.6 - 1 mm = 1 (for each interproximal > 1 mm = 2 <b>contact</b> )
<b>OVERJET</b>  Anterior teeth must be contacting.  0 mm = satisfactory ≤ 1 mm = 1 (for each maxillary > 1 mm = 2 tooth)  Transverse posterior teeth: Mandibular buccal cusps are measured to the central fossa of the maxillary teeth.	<b>ROOT ANGULATION</b>  Parallel = 0 Not parallel = 1 Root contacting adjacent root = 2 (for each <b>occurrence</b> )  Do <b>not</b> score the maxillary and mandibular canines.
<b>NOTE:</b> Gauge Width is 0.5 mm; Gauge Height is 1 mm Third molars are not scored unless they substitute for the second molars. No tooth is scored more than two points per individual parameter.	



# CRE Sample Case

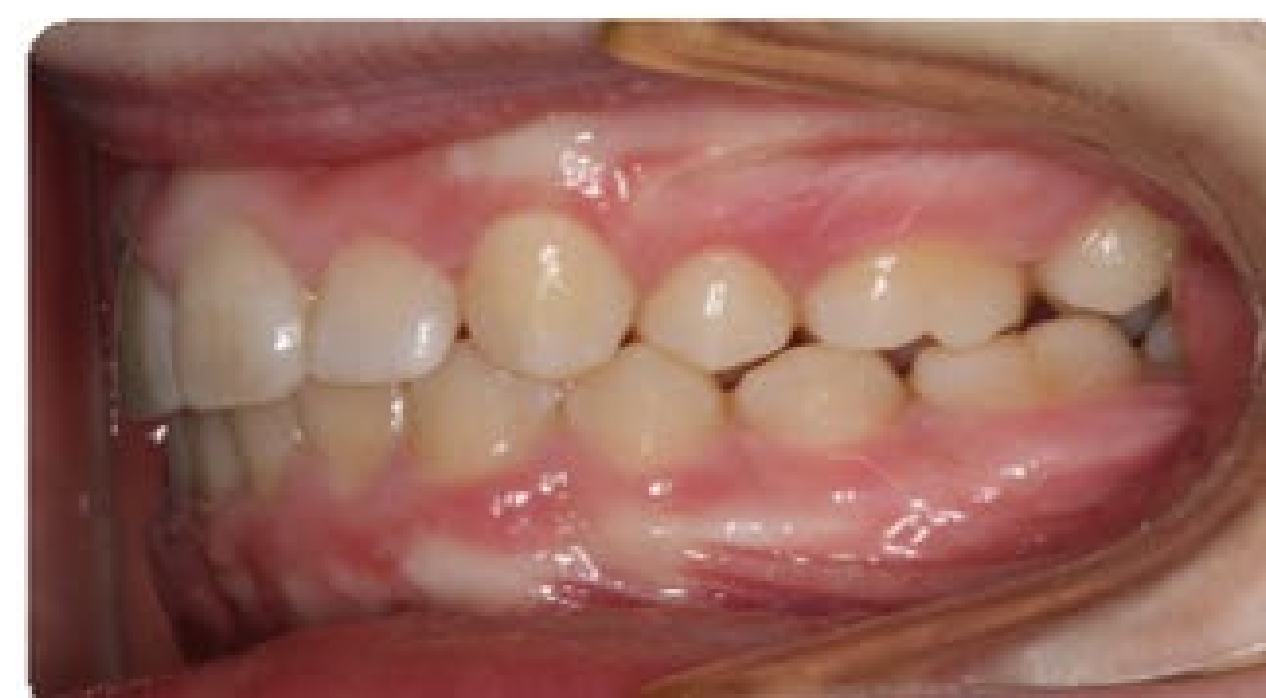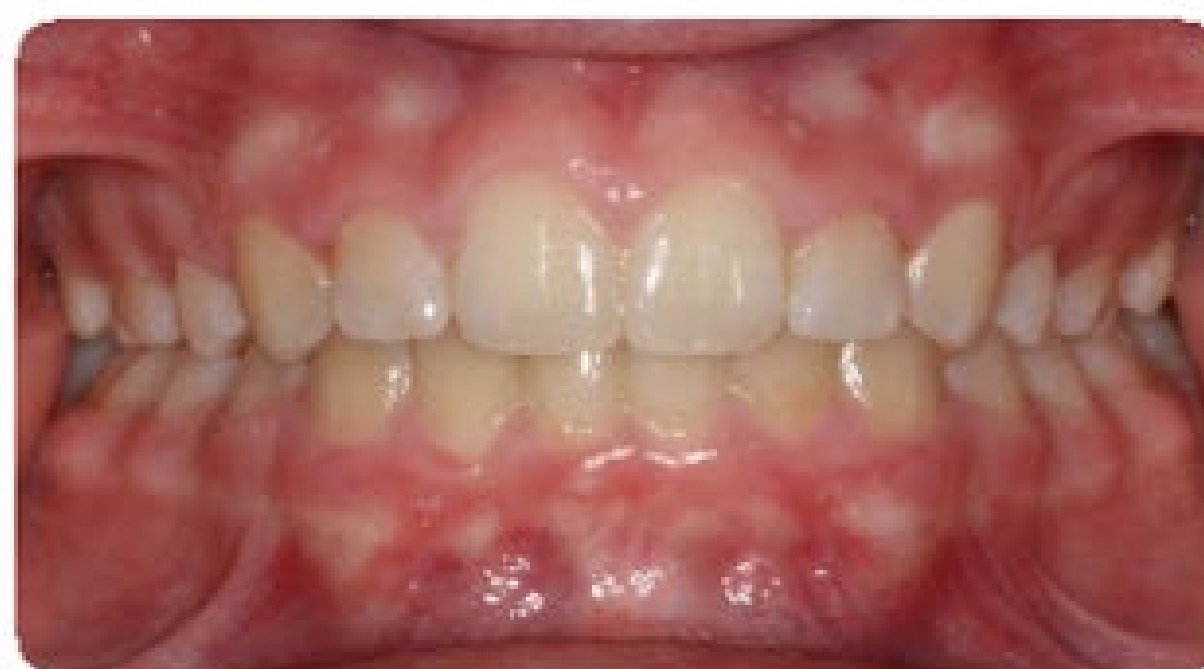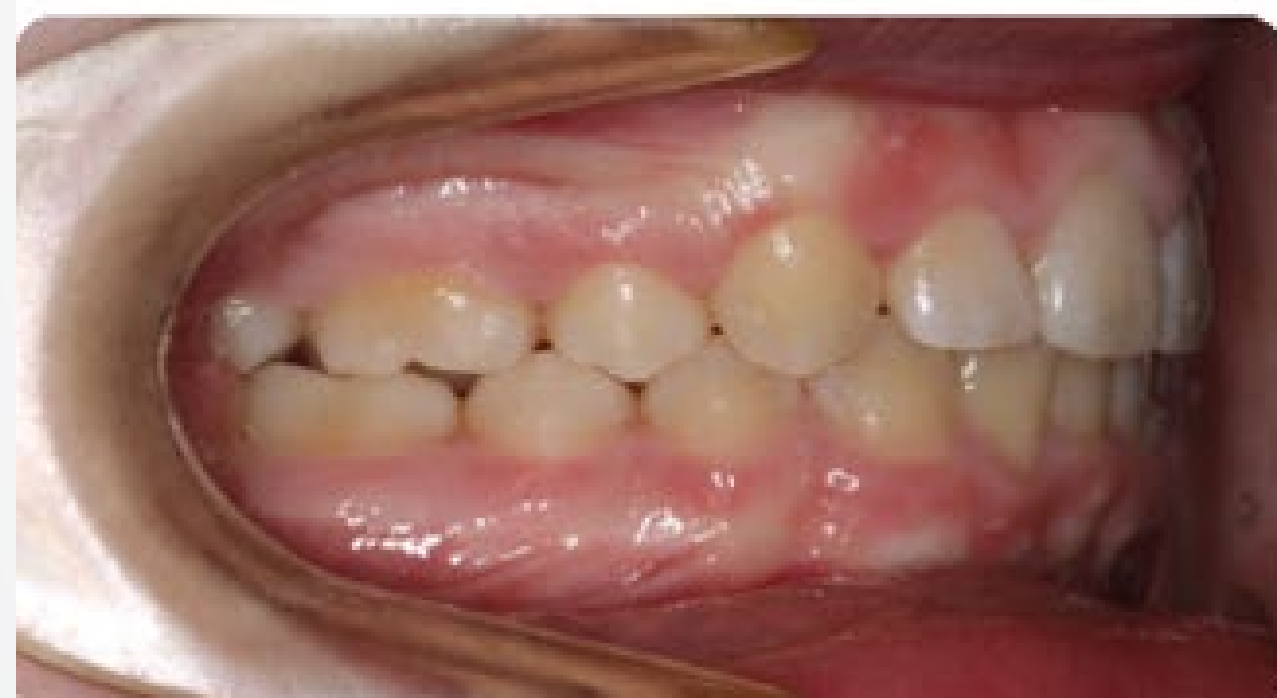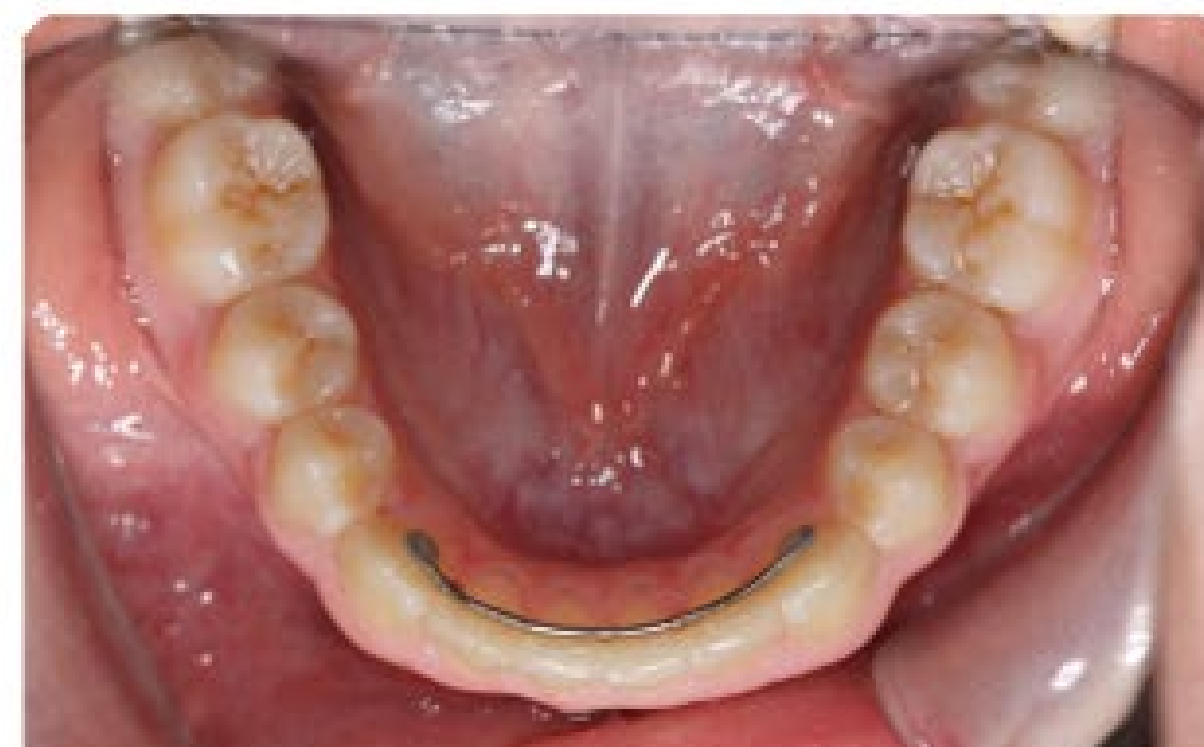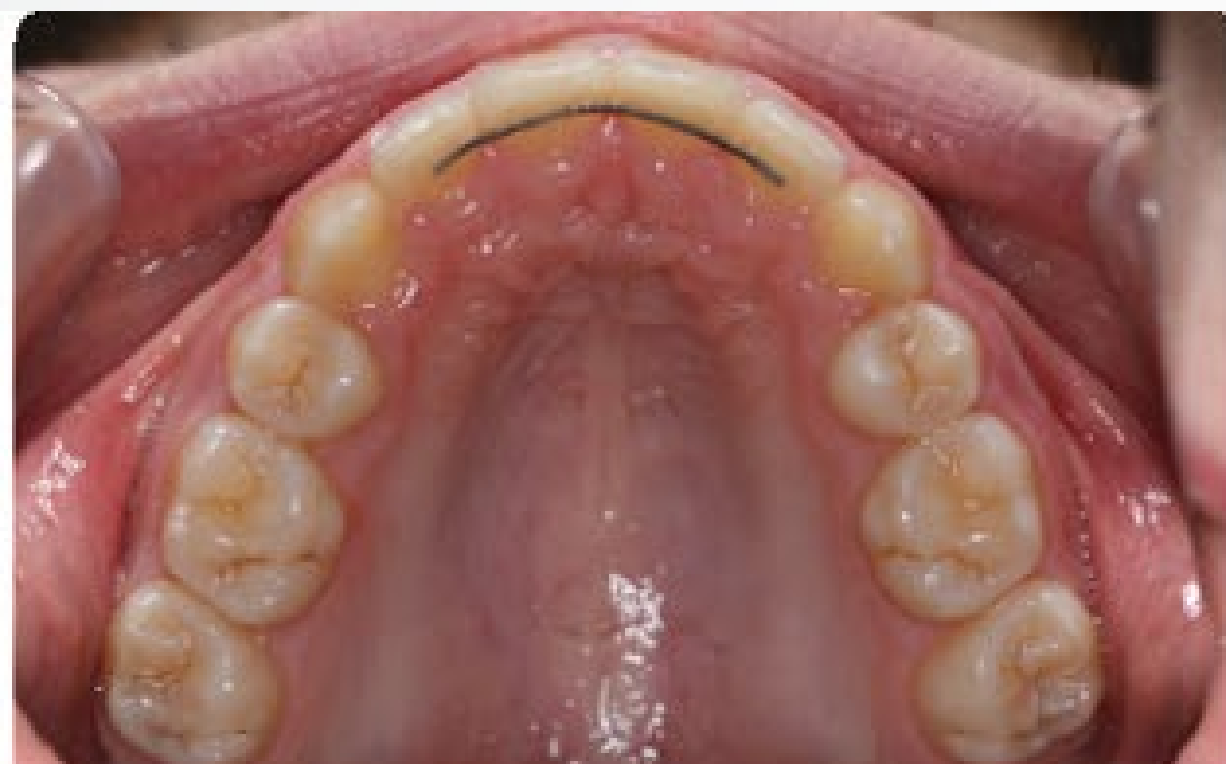## Question 1

### Classification

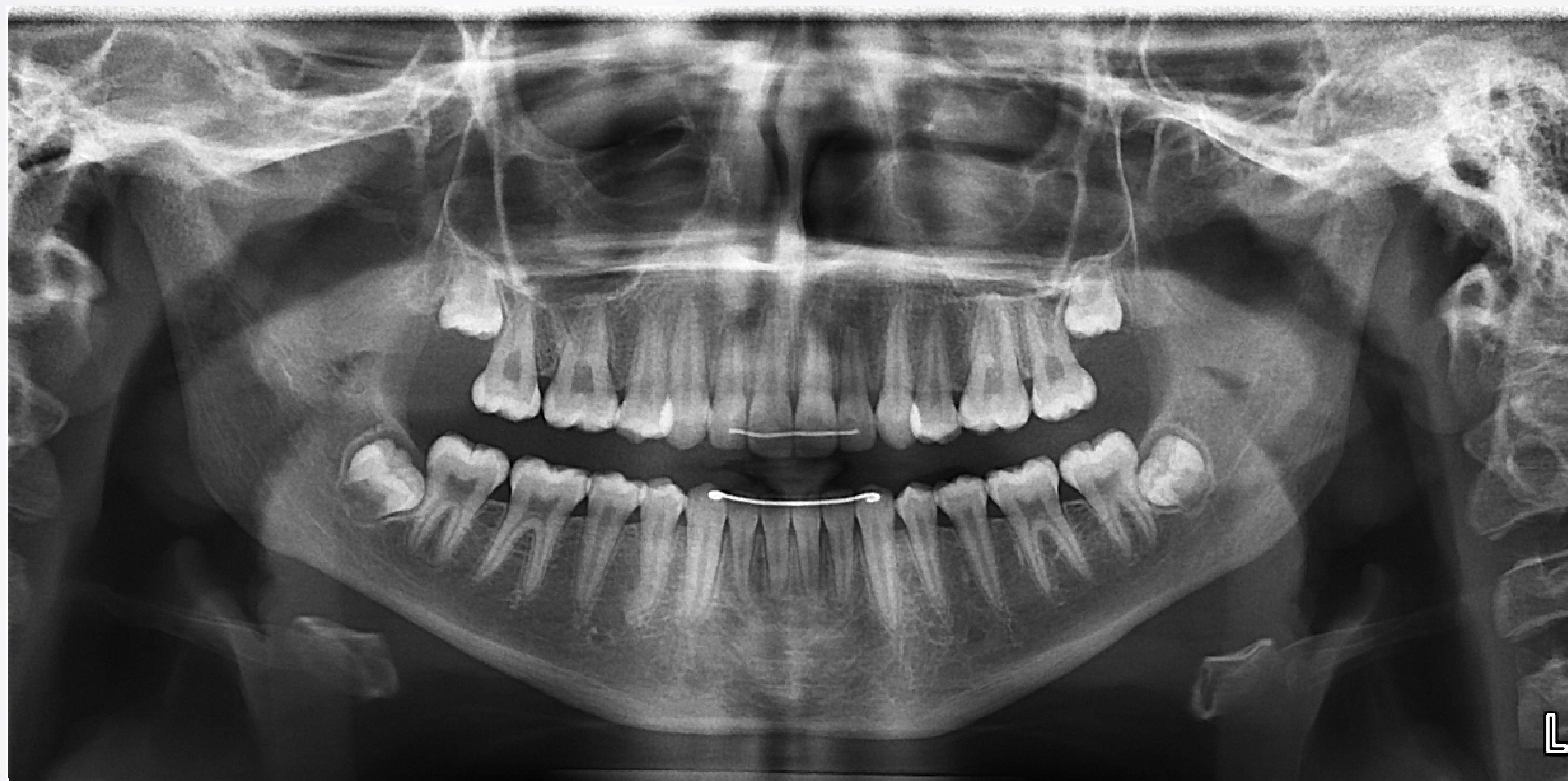Domain 4: Critical Analysis and Outcomes Assessment

### Prompt

When evaluating the final intraoral pictures and the panoramic radiograph of this case, what steps should have been taken to improve the CRE score of 30 for this patient? Please respond in numbered list format below.







# CRE Sample Case

## Question 1

### Classification

Domain 4: Critical Analysis and Outcomes Assessment

### Prompt

When evaluating the final intraoral pictures and the panoramic radiograph of this case, what steps should have been taken to improve the CRE score of 30 for this patient? Please respond in numbered list format below.

# CRE Sample Case

## Question 1

### Fully Proficient Model Response

The examinee's response must include six of the following:

1. Improve maxillary anchorage to control maxillary molar A-P position (loss of anchorage resulted in a super Class II molar)
2. Maxillary expansion to improve posterior overjet (Inadequate posterior OJ)
3. Band/Bracket repositioning or archwire bends to improve marginal ridge discrepancies between first and second molars.
4. Increase-improve maxillary anterior torque (third order bends)
5. Archwire bends or bracket/band reposition to achieve proper occlusal contacts (or allow posterior settling)
6. Second order archwire bends to achieve proper alignment of maxillary molars
7. Correct rotation or second order bend between maxillary right cuspid and lateral incisor
8. Close all posterior interproximal spaces



# CRE Sample Case

## Question 1

### Borderline Proficient Model Response

The examinee's response must include five of the above:

### Not Proficient Model Response

The examinee's response must include four of the above:

# Case Management Form (CMF)

# Case Management Form (CMF)

## Reasons for the ABO Case Management Form

1. Self evaluation (quantified)
2. Evaluation/judgement of each parameter (quantified)
3. Evaluation of records (quantified)
4. Scores can be scored/digitally retrieved (demonstrates trends)
  - A numerical VTO
  - Self evaluation
  - Monitors record quality



# Case Management Form (CMF)

		MEASUREMENTS			
		PRE TX A	PROG A1	POST TX B	DIFF.  A-B
CEPHALOMETRIC	SNA°				0.0
	SNB°				0.0
	ANB°				0.0
	SN-MP°**				0.0
	FMA°				0.0
	DENTAL				
	<u>1</u> TO NA mm				0.0
	<u>1</u> TO SN°				0.0
	<u>1</u> TO NB mm				0.0
ARCH	<u>1</u> TO MP°				0.0
	<u>6</u> TO <u>6</u> WIDTH				0.0
	<u>6</u> TO <u>6</u> WIDTH				0.0
	<u>3</u> TO <u>3</u> WIDTH				0.0
	CURVE OF SPEE				0.0
	MANDIBULAR ARCH FORM				
	FACIAL				
E-LINE	Upper				0.0
	Lower				0.0

# CMF Sample Case

## Question 1

- The examinee will have access to the following records: Initial photo montage, initial intraoral photographs, initial lateral cephalogram, initial cephalometric tracing, and the pre-treatment skeletal analysis (see example below).

	PRE TX A
SNA°	81.0
SNB°	72.0
ANB°	9.0
SN-MP°**	48.0
FMA°	39.0

# CMF Sample Case

## Question 1

### Classification

Domain 2: Treatment Objectives and Planning

### Opening Scenario

A 16-year, 2-month-old female presents with the chief complaint that “My teeth stick out.”

### Prompt

Using the lateral cephalometric analysis and the CMF chart, identify appropriate skeletal treatment objectives. Please respond in numbered list format below.

### Model Responses

The board expects a fully proficient response for this question to include:

1. Increase SNB
2. Decrease ANB
3. Decrease SN-MP
4. Decrease FMA



# CMF Sample Case

## Question 2

- The examinee will have access to the following records: Initial photo montage, initial intraoral photographs, initial lateral cephalogram, initial cephalometric tracing, final photo montage, final intraoral photographs, final lateral cephalogram, final cephalometric tracing, and the pre- /post-treatment skeletal analysis (see example below).

	PRE TX A	PROG A1	POST TX B	DIFF.  A-B
SNA°	81.0		81.0	0.0
SNB°	72.0		70.0	-2.0
ANB°	9.0		11.0	2.0
SN-MP°**	48.0		50.0	2.0
FMA°	39.0		41.0	2.0

# CMF Sample Case

## Question 2

### Classification

Domain 4: Critical Analysis and Outcomes Assessment

### Opening Scenario

A 16-year, 2-month-old female presents with the chief complaint that “My teeth stick out.”

### Prompt

Describe the skeletal changes and your rationale for what occurred. Please respond in numbered list format below.

### Model Responses

The board expects a fully proficient response for this question to include:

1. Decrease in SNB due to inadequate vertical control
2. Increase in ANB due to decrease in SNB (due to/as a result of inadequate vertical control)
3. Increase SN-MP due to inadequate vertical control
4. Increase in FMA due to inadequate vertical control

# CMF Sample Case

## Question 3

- The examinee will have access to the following records: Initial photo montage, initial intraoral photographs, initial lateral cephalogram, initial cephalometric tracing, and the pre-treatment dental analysis (see example below).

	PRE TX A
<u>1</u> TO NA mm	9.0
<u>1</u> TO SN°	111.0
<sup>-</sup> <u>1</u> TO NB mm	16.0
<sup>-</sup> <u>1</u> TO MP°	107.0



# CMF Sample Case

## Question 3

### Classification

Domain 2: Treatment Objectives and Planning

### Opening Scenario

A 16-year, 2-month-old female presents with the chief complaint that “My teeth stick out.”

### Prompt

Identify appropriate dental treatment objectives for the variables in the case management table. Please respond in numbered list format below.

### Model Responses

The board expects a fully proficient response for this question to include:

1. Retract maxillary incisors to NA
2. Retract mandibular incisors to NB
3. Decrease mandibular incisor proclination to MP
4. Decrease maxillary incisor proclination to SN

# CMF Sample Case

## Question 4

- The examinee will have access to the following records: Initial photo montage, initial intraoral photographs, initial lateral cephalogram, initial cephalometric tracing, final photo montage, final intraoral photographs, final lateral cephalogram, final cephalometric tracing, and the pre- /post-treatment dental analysis (see example below).

	PRE TX A	PROG A1	POST TX B	DIFF.  A-B
<u>1</u> TO NA mm	9.0		-2.0	11.0
<u>1</u> TO SN°	111.0		77.0	34.0
<sup>-</sup> <u>1</u> TO NB mm	16.0		9.0	7.0
<sup>-</sup> <u>1</u> TO MP°	107.0		97.0	10.0

# CMF Sample Case

## Question 4

### Classification

Domain 4: Critical Analysis and Outcomes Assessment

### Opening Scenario

A 16-year, 2-month-old female presents with the chief complaint that “My teeth stick out.”

### Prompt

Describe the changes in the maxillary and mandibular incisor position observed in this case. Please respond in numbered list format below.


### Model Responses

The board expects a fully proficient response for this question to include:

1. Excessive retraction of maxillary incisors
2. Lack of torque control in maxillary incisors (resulting in retroclination of the maxillary incisors)
3. Retraction of mandibular incisors
4. Adequate torque control of mandibular incisors



# Case Management Form

- Remember 3 planes of space
  - Use precise and concise description
  - Use appropriate terminology
  - Treatment objectives and treatment plan should be in line with patient's needs not wants
  - Actively participate in academic or study club case reviews
- 

# Superimpositions

# Superimposition Sample Case

Examinees will be presented with a combination of the following case records, as needed:

- Initial photo montage
- Initial intraoral photographs
- Initial panoramic radiograph
- Initial lateral cephalogram
- Initial hand-wrist radiograph
- Final photo montage
- Final intraoral photographs
- Final panoramic radiograph
- Final lateral cephalogram
- Final superimpositions



# Superimposition Sample Case

## Question 1

### Classification

Domain 4: Critical Analysis and Outcomes Assessment

### Prompt

Assuming the time between initial and final records was 34 months, what dental changes occurred as a direct result of treatment? Please respond in numbered list format below.

### Model Responses

The number of responses required to attain a fully proficient or borderline proficient score will depend on the changes that are observed in the superimposition relative to normal growth during the treatment interval.

# Superimpositions

- Know radiographic analysis
  - Review all 3 ABO superimposition videos (ABO website)
  - Master superimposition interpretation skills
  - Be able to differentiate changes from growth and treatment mechanics
  - Read Buschang/Tadlock Guidelines for Assessing Growth and Development of the Orthodontic Patient. Seminars in Orthodontics, 2017
- 